



# IMAGE OF THE MONTH

**07/2021**

## FROM YOUNG ESPGHAN

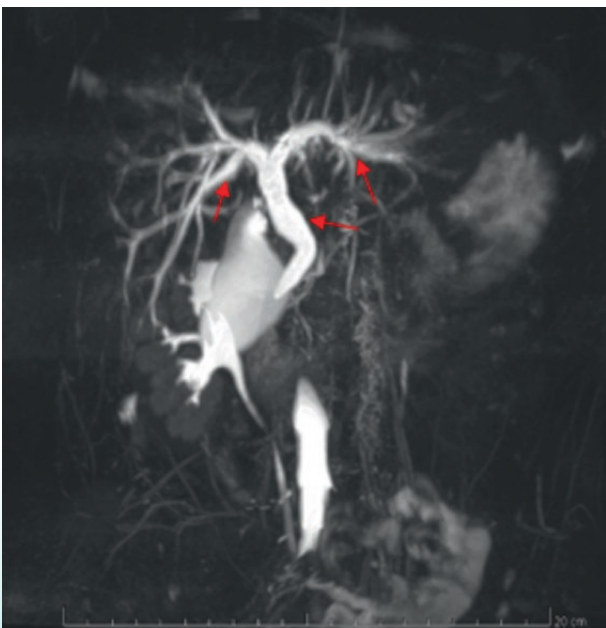
**Jessica Lecarpentier, Nathalie Rock***Swiss pediatric liver center,  
University hospital Geneva  
Geneva, Switzerland*

### Primary Sclerosing Cholangitis (PSC) and Ulcerative colitis (UC).

A 12 years old female patient was referred for chronic abdominal pain, profuse diarrhea, rectal bleeding and asthenia. The initial assessment showed an increased fecal calprotectin associated with an inflammatory syndrome and abnormal liver function test. The PUCAI was evaluated at 40. Upper and lower endoscopy showed a pancolitis. Histology demonstrated chronic inflammation of the colonic mucosa with micro erosive infiltration of the surface of the epithelium and crypts. The MR enterography of the small intestine was normal except for bile duct dilatation. We then performed an MR cholangiography (Figure 1) demonstrating multiple strictures scattered along large intrahepatic bile ducts and the choledochal duct. The assessment of primary sclerosing cholangitis (PSC) returned positive for p-ANCA. Liver biopsy showed no significant histological changes. The patient then received induction therapy with prednisone and azathioprine. Ursosfalk was added due to the PSC.

PSC has to be considered in any case of UC. P-ANCA is a very valuable biomarker for PSC with a high specificity in terms of discrimination of PSC against other liver diseases including ASC and AIH. Thus, inclusion of p-ANCA measurement in routine work-up of IBD is highly recommendable.

Learn more about UC and PSC in Cara L. Mack, . *Diagnosis and Management of Autoimmune Hepatitis in Adults and Children. 2019 Practice Guidelines From the American Association for the Study of Liver Diseases. Hepatology. 2020 Aug;72(2):671-722.*



**Figure 1:**  
cholangio-MRI showing dilation of the intra- and extrahepatic ducts, with caliber irregularities. Right hepatic duct measuring 6.5mm and left 7mm in diameter. Regular dilation of the common bile duct measuring up to 10mm of diameter.