



IMAGE OF THE MONTH

07/2020

FROM YOUNG ESPGHAN

Anne-Marie Grima
Young ESPGHAN committee
Mater Dei Hospital, Malta

A 12-year old girl presented with a 3-month history of abdominal pain, weight loss and low-grade fever. A diagnosis of Crohn's disease with terminal ileitis was made on histological and radiological evidence. She received induction treatment with prednisolone 2mg/kg for 2 weeks which was then weaned down over a total period of 8 weeks and infliximab 5mg/kg at 0, 2, 6 weeks and then maintained on 8 weekly doses of infliximab.

At 12 weeks from presentation, she started complaining of right iliac fossa pain, dysuria, macroscopic haematuria and pyuria.

Repeat MRI enterogram showed mural thickening and increased mucosal enhancement of the distal ileum and a 4cm enhancing mass with a cystic centre representing an inflammatory phlegmon. Inflammatory changes at the site of contact with uterus and bladder were noted. MR pelvis showed a fistula between the terminal ileum and the bladder wall.

The patient received antibiotics for three months (co-amoxiclav and metronidazole as per local hospital policy) and infliximab dose and frequency was adjusted according to therapeutic levels.

Enterovesical fistula is a potential complication of patients with terminal ileitis due to Crohn's disease who present with evidence of urinary tract infection.

Learn more on the medical management of fistulizing Crohn's disease by reading the Consensus Guidelines of ECCO/ESPGHAN on the medical management of Paediatric Crohn's disease <https://doi.org/10.1016/j.crohns.2014.04.005>

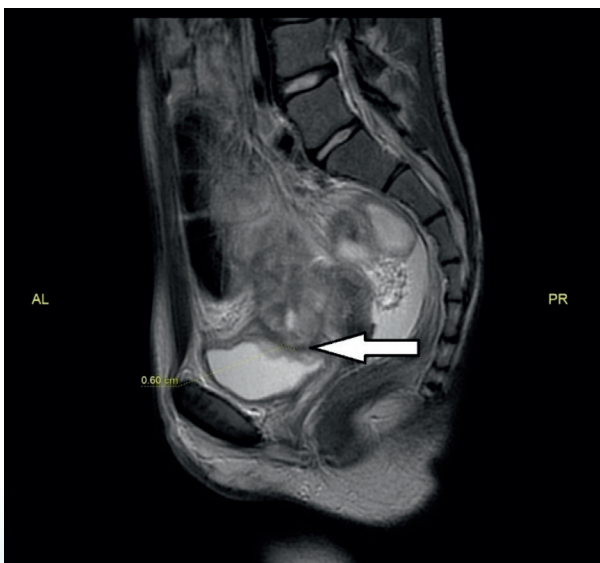

Fig 1: enterovesical fistula at diagnosis

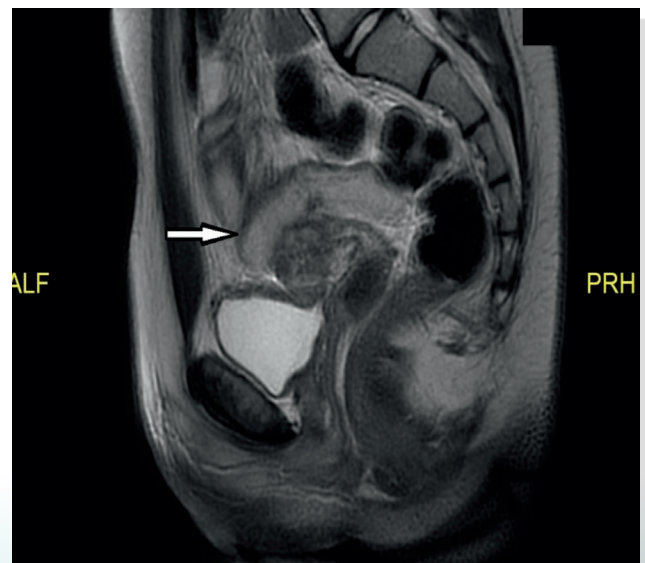


Fig 2: closure of fistulous tract and resolution of terminal ileal inflammation 11 months post diagnosis