

Case of the Month

APPLICATION FORM

Case Title: From severe anemia to intestinal hemangiomatosis – a bumpy road

Applicant Name **Raluca Maria Vlad**

Applicant Institute **Carol Davila University of Medicine and Pharmacy**

Institute City and Country **Bucharest, Romania**

Applicant Contact Email ralu_neagoe@yahoo.com

Brief case description (max. 300 words)

A 6 year old girl was admitted in our department in February 2019 for refractory anemia. She had severe anemia since August 2018 (minimum Hgb level=2.8 g/dl). Hemoglobin values continued to decrease with treatment (blood transfusions, injectable iron), without a history of active bleeding.

On admission, the patient demonstrated pallor and failure to thrive. Investigations revealed severe regenerative anemia (Hgb=6.6g/dl), hyposideremia, anisocytosis, poikilocytosis, with normal leukocyte and platelet counts, no inflammatory syndrome, normal fecal calprotectin and positive fecal occult blood test (FOBT).

Abdominal ultrasound and abdominal-pelvic CT returned normal findings in our case. Upper digestive endoscopy and colonoscopy did not reveal any signs of active bleeding and the pathology was unremarkable. Tc⁹⁹ scintigraphy did not find a Meckel diverticula.

In March 2019, on exploratory laparotomy, six vascular tumors were detected and removed alongside the ileum. Pathology confirmed intestinal hemangiomatosis.

Two months later the patient had an increasing weight curve, Hgb=12.1 g/dl, negative FOBT. She is now 10 years old and asymptomatic.

Pictures (add related picture(s) below - resolution min. 72 DPI)

--	--

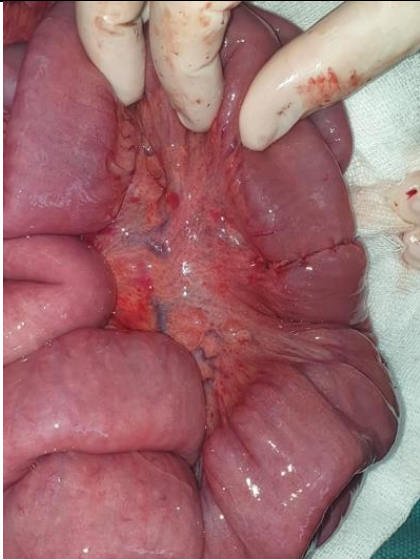

Fig.1

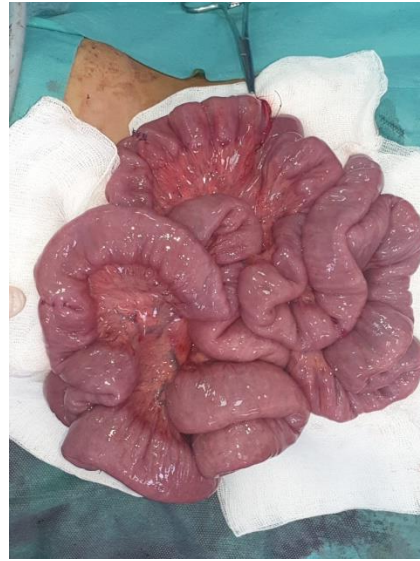

Fig.2

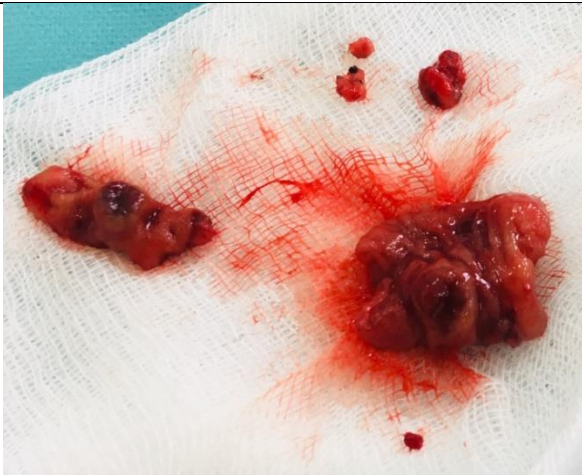

Fig. 3

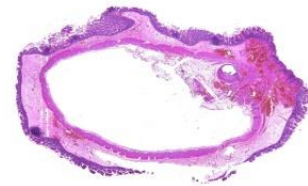


Fig.4

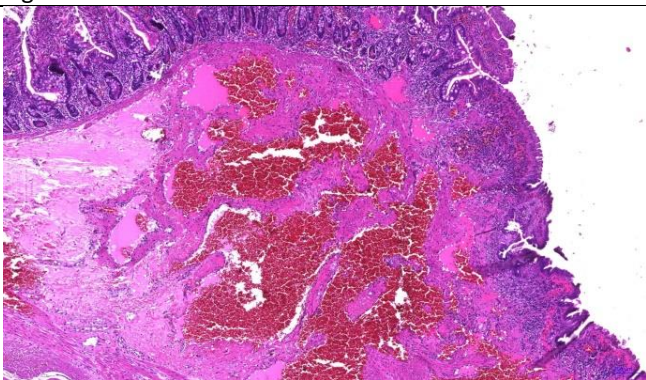


Fig.5

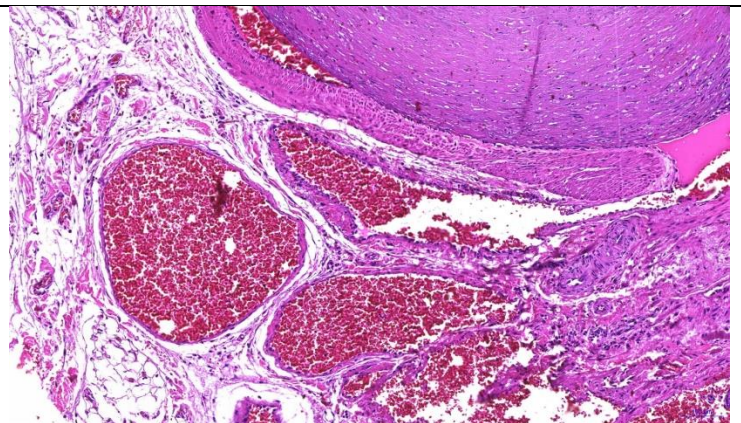


Fig.6

Figure (add description below)

Fig.1: Laparotomy aspect – macroscopic aspect of vascular ileal tumor

Fig.2: Laparotomy – post-excisions aspect of the small bowel

Fig.3: Excised vascular tumors – 6 specimens of different sizes (2mm to 11 cm in diameter)

Fig.4: Intestinal biopsy (ileon specimen) – mucosal bleeding - Hematoxylin-Eosin (HE) Staining 1 - 35.278_0.4x

Fig.5: Intestinal biopsy (ileon specimen) – vascular structures filled with erythrocytes (intestinal hemangiomatosis)-HE 1 - 35.278_5.0x

EUROPEAN SOCIETY FOR PAEDIATRIC GASTROENTEROLOGY, HEPATOLOGY AND NUTRITION

ESPGHAN Office
Rue Pellegrino Rossi 16
1201 Geneva, Switzerland
[t] +41 (0)22 900 04 01

[e] office@espghan.org [w] www.espghan.org

Fig.6: Intestinal biopsy (ileon specimen) – vascular structures filled with erythrocytes (intestinal hemangiomatosis)-HE 1 - 35.278_10.0x2

EUROPEAN SOCIETY FOR PAEDIATRIC GASTROENTEROLOGY, HEPATOLOGY AND NUTRITION

ESPGHAN Office

Rue Pellegrino Rossi 16
1201 Geneva, Switzerland

[t] +41 (0)22 900 04 01

[e] office@espghan.org [w] www.espghan.org