



# IMAGE OF THE MONTH

**01/2023**

## FROM YOUNG ESPGHAN

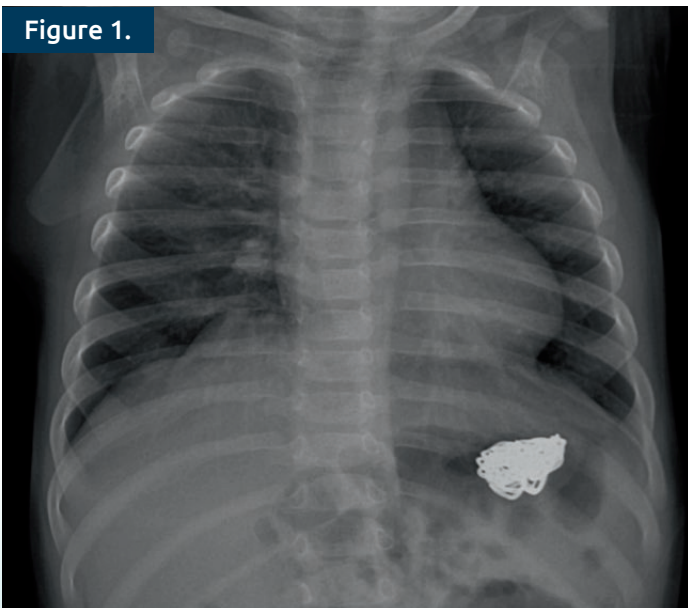
**Duygu Demirtas***Van Training and Research Hospital  
Van, Turkey*

### An unusual case of foreign body ingestion

An 8-month-old boy was admitted to the Pediatric Emergency Service with a runny nose, and sneezing. He had vomited twice. No hematemesis or bilious vomiting was reported. His abdominal examination was normal. An opacity consistent with a foreign body in the stomach was visible on the chest X-ray. Under general anesthesia and endotracheal intubation, upper gastrointestinal endoscopy was carried out. A bracelet was discovered in the fundus, and it was successfully removed from the stomach using an alligator mouth forceps. The patient's mother revealed that the bracelet was hers and the patient's 7-year-old brother may have forced the patient to ingest it. It's unclear if the vomiting was caused due to the bracelet. However, it's important to consider the possibility of a foreign body ingestion in the stomach even if an infant vomits without blood. Unwitnessed foreign body ingestions should be considered in infants with vomiting (1, 2).

#### References:

- 1 Jayachandra S, Eslick GD A systematic review of paediatric foreign body ingestion: presentation, complications, and management. *Int J Pediatr Otorhinolaryngol* 2013;77(3):311-7.
- 2 Paul SP, Hawes D, Taylor TM Foreign body ingestion in children: case series, review of the literature and guidelines on minimising accidental ingestions. *J Fam Health Care* 2010;20(6):200-4.

**Figure 1.****Figure 1.** Chest X-ray demonstrates an opacity in the stomach**Figure 2.****Figure 2.** Bracelet removed from the stomach