



IMAGE OF THE MONTH

03/2021

FROM YOUNG ESPGHAN

Dimitrios Tapsas*Medical School, Aristotle University
Thessaloniki, Greece*

Case of a rare form of gastritis

History

A 16 year old boy was referred for further investigation of daily abdominal pain and persistent iron deficiency (S-Fe 4 g/dl; normal range 13-16 g/dl, S-ferritin 10ng/ml; normal range 23-70 ng/ml).

Further investigation revealed normal values for; Hb, MCV, f-Helicobacter pylori, tTG-IgA and fecal Calprotectin. Gastroscopy revealed increased nodularity of the gastric mucosa, mucosal edema, erythema and hyperplastic rugae suggestive of collagenous gastritis (Fig.1).

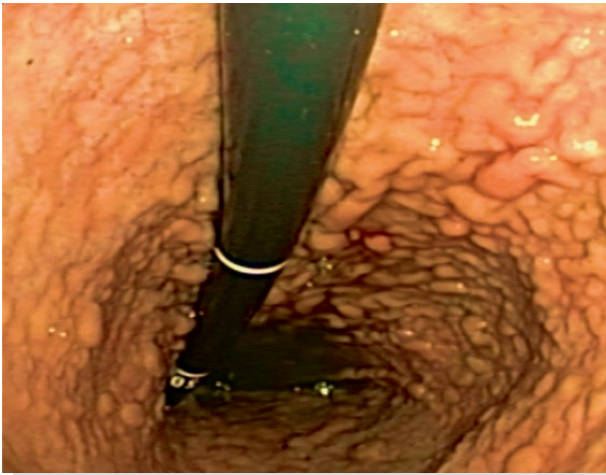


Figure 1:

Macroscopically nodularity of the gastric mucosa, mucosal edema, erythema and hyperplastic rugae.

Histology demonstrated subepithelial deposition of collagen bands and inflammatory cell infiltration in the lamina propria - typical for collagenous gastritis.

The pathophysiology remains unclear but it has been hypothesized to be due to the deposition of the collagen bands, protein exudate occurs leading to increased vascular permeability. There are two forms of the disease described in the literature, the pediatric and the adult form. The pediatric form only involves the stomach while in the adult form the collagen deposition can be seen throughout the gastrointestinal tract. Only few pediatric cases have been reported so far. Median age 12 y.o. The most common symptoms among pediatric patients are iron deficiency and anemia (71%), abdominal pain (41%), nausea and vomiting (14%), other (17%).

No curative treatment has been identified up to date.

Oral iron supplementation is the first hand treatment in all cases. Some patients experience relief of symptoms after PPI treatment. Experimental treatments include prednisone, budesonide, sucralfate and mesalamine. In this case the patient received repeatedly oral iron supplementation because of recurrent iron deficiency.

References:

1. Käppi T, *et al.* Collagenous Gastritis in Children: Incidence, Disease Course, and Associations With Autoimmunity and Inflammatory Markers / Clin Transl Gastroenterol. 2020 Aug
2. Lee YJ, *et al.* Three case reports of collagenous gastritis in children: Lessons for an endoscopic and histologic approach to mucosal nodularity of the stomach / Medicine (Baltimore) 2019